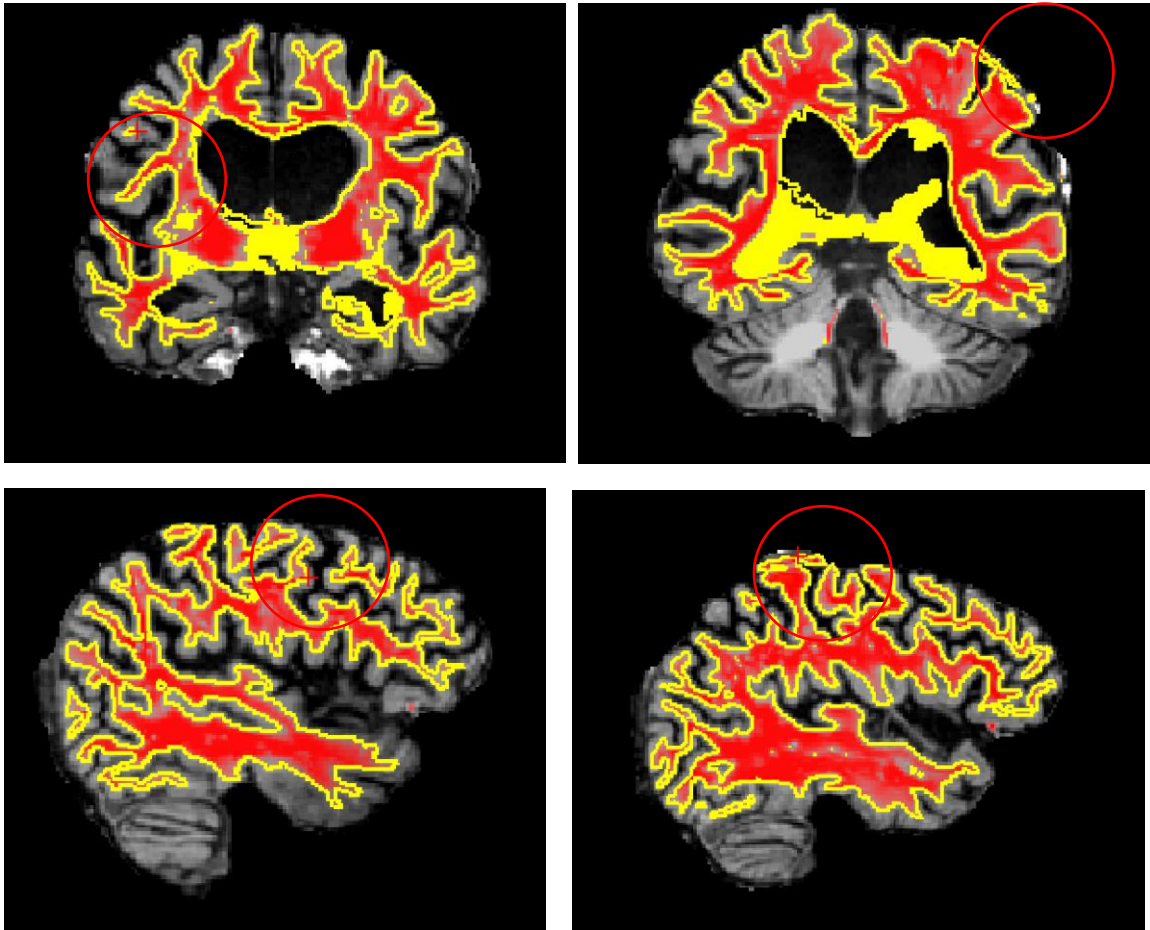


SUBJ with trouble



- 1) Parietal lobe I though was missing in coronal looks fine in sagittal view.
- 2) Right pictures both show no clear strip of the brain skull, is that so?

SUBJ without trouble

