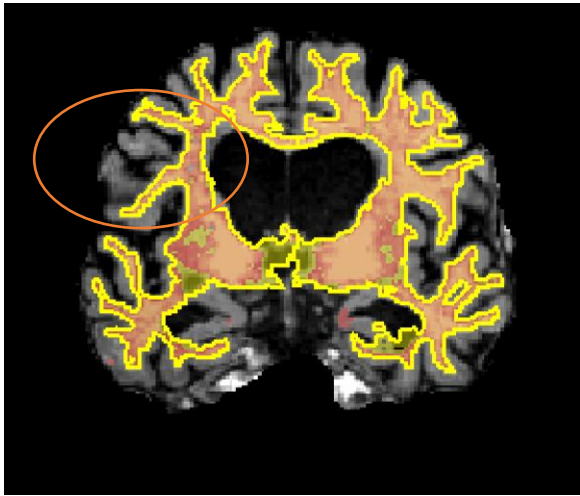


SUBJ scan with trouble



Left parietal lobe seems missing from the surface

SUBJ scans with no trouble

